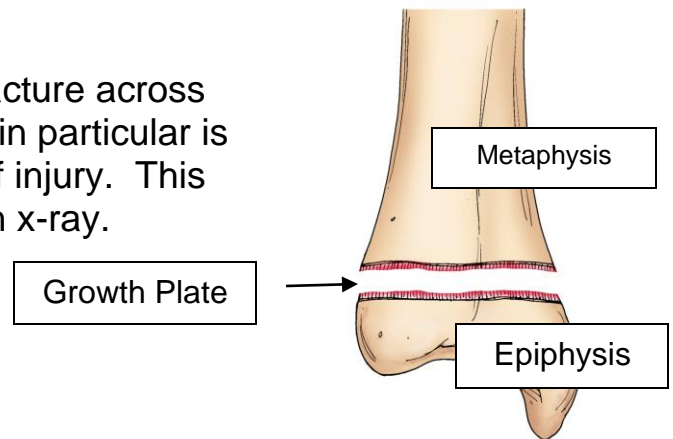


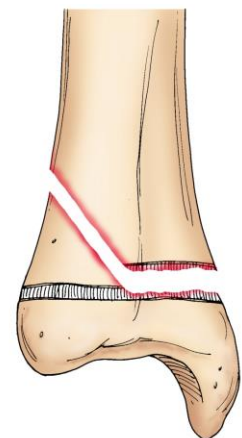
# GROWTH PLATE INJURIES

Growth plate injuries occur only in the growing child because once the child is finished growing the growth plate disappears. On x-ray the growth plate appears as a dark line that is near the end of the bone. The growth plate is responsible for making each bone become longer and bigger. Because most of the growth plate is a soft gristle-like material it is more easily injured than the rest of the bone. The amount of pressure or force applied to the bone and the direction of that force determines the type of fracture that results. The Salter-Harris classification of growth plate fractures can be used to describe the vast majority of abnormal x-rays.

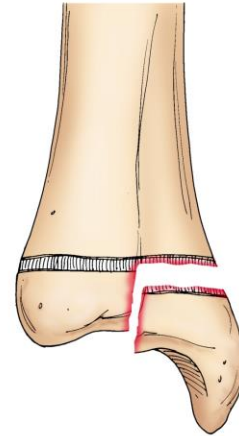
**Salter-Harris I:** This is a transverse fracture across the entire growth plate. The distal fibula in particular is at greatest risk for sustaining this type of injury. This type of fracture is often difficult to see on x-ray.



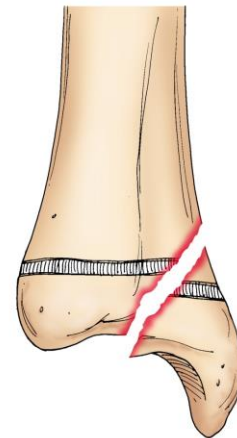
**Salter-Harris II:** This fracture extends 50% to 85% across the growth plate and then the fracture line turns into the bony part of the long bone and exits through this bony area. Sometimes this is inaccurately referred to as being a chip fracture. These fractures are particularly at risk for displacing or angulating.



**Salter-Harris III:** This fracture extends across the growth plate and then turns and exits into the joint. This splits the growth center into two pieces. Not only is the growth potential of the physal plate affected but also the growth of the epiphysis may be affected in this particularly serious type of injury. Displacement of this type of fracture results in irregularity of the joint surface and early arthritis.



**Salter-Harris IV:** This fracture extends from within the joint, across the epiphysis, the epiphyseal plate and into the metaphysis of the bone. These fractures are the most likely to cause growth disturbances because bone can form across the growth plate. They must be repaired to near anatomic alignment to provide the best chance for the bone to resume normal growth. Even then the damage to the growth plate may so severe that normal growth is no longer possible.



**Salter-Harris V:** Pressure is applied to the bone in such a way that the central portion of the growth plate is crushed. X-rays may not show the injury but the growth plate does not resume normal growth and the limb grows more slowly than the normal opposite side.



©John T. Killian, M.D. & Sharon Mayberry, M.D.